NOTE *Anatomy*

The Arterial Supply of Meckel's Diverticulum in Geese (*Anser anser domesticus*)

Kamil BESOLUK[1)] and Emrullah EKEN[1)]

[1)]*Department of Anatomy, Faculty of Veterinary Medicine, University of Selcuk, Campus, 42031, Konya-Turkey*

(Received 17 May 2001/Accepted 15 August 2001)

ABSTRACT. This study was carried out to describe the arterial supply of Meckel's diverticulum (MD) in geese, using 36 adult healthy geese of both sexes, 50 to 52 weeks of age. The arterial supply of MD was classified into three types, In the first type, MD was supplied by a very distinct branch from the cranial mesenteric artery in 21 geese. In the second type, it was supplied by one terminal branch from the cranial mesenteric artery in 9 geese. In the third type, it was supplied both by one branch from the jejunal artery and by terminal branch from the cranial mesenteric artery in 6 geese. Based on the these types, we found significant differences ($p \leq 0.01$) in the length of MD between type I and II. The blood supply of the third type was observed more frequently in the male than in the female. Results from this study may contribute to the anatomical knowledge of arterial supply of MD in the geese.

KEY WORDS: blood supply, Meckel's diverticulum, goose.

J. Vet. Med. Sci. 63(12): 1343–1345, 2001

In the developing chick embryo, the yolk duct is the peduncle that attaches the yolk sac to the intestines and is the means whereby the vitelline blood vessels enter the embryo [1]. Moreover, in the post-hatching period, significant amounts of yolk may pass through the yolk duct into the intestine [19]. The yolk duct and sac continue to grow after hatch [10, 15] and persist throughout the life of both sexes of the domestic fowl as an appendage of the small intestine [3, 10, 14]. It is known as diverticulum caecum vitelli [14] or vitelline diverticulum [13] and is referred to as MD. In 80% of ducks and 90% of geese a well-developed MD is present at the apex of the axial loop of the jejunum [3]. In the duck and goose it persists for a long time but in the other species it disappears early in life [14]. Some researchers studied on the blood flow measurements [4, 7, 22] and developmental changes in the yolk sac circulation of the avian embryo [5, 6, 18]; others described the function [15, 16], morphology [20] and position [1] of MD in post-hatching period.

Immunologic studies were carried out on MD [8, 9], and it is of clinical significance because of sometimes having pathologic changes [2, 17, 21]. Therefore, the exact anatomical knowledge of blood supply to MD is necessary for future studies, and for proper diagnosis of pathologic disorders in MD. In the literature, however, very little was known on the arterial supply of Meckel's diverticulum in birds. In the present study, we described the arterial supply of MD, and the vascular system was classified into three types.

A total of 36 adult healthy domestic geese of both sexes was used as materials. They were native breeds in Turkey, 50 to 52 weeks of age, and weighed between 4–4.5 kg. Animals were reared in the departmental poultry house of Selcuk University in hygienic condition, with food and water *ad libitum*. They were anaesthetised with 25 mg/kg ketamin HCl (Ketanez® - ALKE, Istanbul, Turkey), IM. Under anaesthesia, they were killed by exsanguination from the abdominal aorta without regaining consciousness following the opening of the abdominal cavity with a median incision. Plastic tubes were inserted and tied to the abdominal aorta immediately cranial to the cranial mesenteric artery in a cranial direction. The vessels were rinsed with 0.9% physiological saline. Red (Setacolor™, cardinal red, num. 24, PEBEO, Cedex, France)-coloured latex (Rubber latex™, MERCAN, Istanbul, Turkey) were injected into the abdominal aorta. Two days later, they were fixed with 10% formalin. Then, the arterial supply of MD was revealed by fine dissection, and the observations were recorded and photographed. All morphometrical measurements related to MD (length: cranial to caudal; width: lateral to medial; height: dorsal to ventral) were performed by callipers (AESCULAP VA 110). All statistical analyses were accomplished with the Statistical Package for the Social Sciences (SPSS 6.0) computer package.

Relationships between the various data related to MD and the type of arterial system were shown in Table 1.

In the present study, MD situated at the axial lobe of the jejunum was supplied by the branches originating from the cranial mesenteric artery in all geese. These branches, however, were varied in their courses and origins thus dividing into 3 groups as follows.

In the first type, MD was supplied blood by a highly prominent branch of the cranial mesenteric artery in 21 (58%) geese (9 male, 12 female). This branch, approximately 5 cm in length, inclined directly to MD and ended in

Table 1. Relationships between morphometric measurements of MD and its vascular types in domestic geese

	Length (mm)	Width (mm)	Height (mm)
Type I	$13.76 \pm 0.14^{a)}$	$4.67 \pm 0.13^{a)}$	$3.51 \pm 0.09^{a)}$
Type II	$13.12 \pm 0.16^{b)}$	$4.41 \pm 0.13^{a)}$	$3.39 \pm 0.11^{a)}$
Type III	$13.32 \pm 0.12^{ab)}$	$4.48 \pm 0.08^{a)}$	$3.43 \pm 0.08^{a)}$

Different letters mean that differences among the means of different groups in the same column are statistically significant ($p \leq 0.01$). Data expressed as mean ± SEM.

Figs. 1, 2, 3. a) axial lobe of jejunum; b) MD; c) cranial mesenteric artery; d) jejunal artery; e) specific branch from cranial mesenteric artery for MD; f) terminal branch from cranial mesenteric artery for MD; g) branch from jejunal artery for MD.

Fig. 1. The first type; MD is supplied by a specific branch from the cranial mesenteric artery.

Fig. 2. The second type; MD is supplied by one terminal branch from the cranial mesenteric artery.

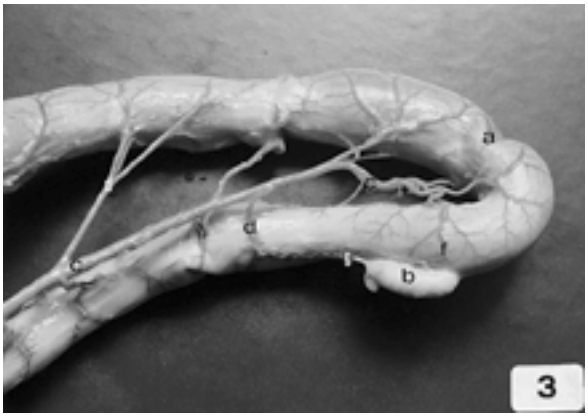

Fig. 3. The third type; MD is supplied both by one branch from the jejunal artery and by one terminal branch from the cranial mesenteric artery.

the base of MD, passing through between the jejunum and the body of MD. Running on the surface of the jejunum, it gives medially many branches to the jejunum (Fig. 1).

In the second type, MD was supplied by one of the terminal branches of the cranial mesenteric artery in 9 (25%) geese (4 male, 5 female). This branch, at first, extended in the mesentery, run transversely on the jejunum providing with several branches and then terminated in the base of MD (Fig. 2).

In the third type, MD was supplied both by one branch from the jejunal artery and by one terminal branch from the cranial mesenteric artery in 6 (16.6%) geese (5 male, 1 female). Forming a single trunk between the jejunum and MD, it distributed on the free medial edge of MD. Running on the surface of the jejunum, both branches gave many fine branches to the jejunum (Fig. 3).

Although MD was reported to be present in 90% of geese [3], we found that MD is seen as a well-developed permanent structure in all geese as reported by Kar [10]. MD located at the axial lobe of the jejunum is supplied by several branches from the cranial mesenteric artery [3]. In our study, however, we recorded that it was supplied both by one branch from the vessel mentioned above and by one from the jejunal artery. Although the jejunum was reported to be supplied either by the jejunal arteries originating from the celiac arteries in the goose [12] or by the jejunal arteries originating both from the cranial mesenteric and celiac arteries in the domestic fowl [11], they did not describe the vascular supply to MD in their works. In the present study, however, we showed that arterial system in MD could be classified into three types. Based on the these types, we found important differences ($p \leq 0.01$) in point of the length of MD between type I and II. Moreover, it was very interesting that the third type blood supply of MD was seen frequently in the male (83.3%), and rarely in the female (16.6%).

In conclusion, it was found that the blood supply of MD in geese was classified into three types. We hope that this study will shed light on future studies on MD, and proper diagnosis of pathologic disorders related to the blood supply.

ACKNOWLEDGEMENT. The authors are deeply grateful to Dr. Seyfullah Haliloglu for his technical assistance in statistical analysis of data.

REFERENCES

1. Branton, S. L., Lott, B. D., Morgan, G. W. and Deaton, J. W. 1988. *Chickens. Poultry Sci.* **67**: 677–679.
2. Chawla, R. S., Singh, B. and Grewal, G. S. 1973. *Fowls. Indian J. Poultry Sci.* **8**: 59–63.
3. Getty, R. 1975. Sisson and Grossman's the Anatomy of the Domestic Animals, vol. 2, 5th ed., W. B. Saunders Co., Philadelphia.
4. Gush, R. J., Thompson, J. M. and Weiss, J. B. 1990. *J. Med.*

Eng. Technol. **14**: 205–209.
5. Hogers, B., De Ruiter, M. C., Baasten, A. M., Gittenberger-de Groot, A. C. and Poelmann, R. E. 1995. *Circ. Res.* **76**: 871–877.
6. Honda, H. and Yoshizato, K. 1997. *Dev. Growth Differ.* **39**: 581–589.
7. Hu, N., Ngo, T. D. and Clark, E. B. 1996. *Cardiovasc. Res.* **31**: 127–131.
8. Jeurissen, S. H., Janse, E. M. and Koch, G. 1988. *Adv. Exp. Med. Biol.* **237**: 599–605.
9. Jeurissen, S. H., Wagenaar, F. and Janse, E. M. 1999. *Poult. Sci.* **78**: 965–972.
10. Kar, A. B. 1947. *Poultry Sci.* **26**: 108–110.
11. Kuru, N. 1996. Macroanatomic Investigations on the Course and Distribution of Aorta in Domestic Fowl and New Zealand Rabbit, PhD thesis, Graduate School of Natural and Applied Sciences, Konya-Turkey.
12. Malinovsky, L. and Visnanska, M. 1975. *Folia Morphol.* **23**: 128–135.
13. Mc Lelland, J. 1990. A Colour Atlas of Avian Anatomy, Wolfe Publishing Ltd., London.
14. Nickel, R., Schummer, A. and Seiferle, E. 1977. Anatomy of the Domestic Birds, Verlag Paul Parey, Berlin.
15. Olah, I. and Glick, B. 1984. *Anat. Rec.* **208**: 243–252.
16. Olah, I., Glick, B. and Taylor, R. E. 1984. *Anat. Rec.* **208**: 253–263.
17. Pecka, Z. 1992. *Folia Parasitol.* **39**: 105–114.
18. Plasswilm, L., Hoper, J. and Sauer, R. 1996. *Strahlenther Onkol.* **172**: 260–264.
19. Romanoff, A. L. 1960. The Avian Embryo, Structural and Functional Development. McMillan, New York.
20. Scharra, D. M., Brito, D. B. and De Figueiredo, J. B. 1976. *Rev. Bras. Biol.* **36**: 223–227.
21. Sugiyama, M., Isoda, M. and Tomizawa, A. 1983. *Jpn. J. Vet. Sci.* **45**: 383–385.
22. Van Golde, J., Mulder, T., Straaten, H. and Blanco, C. E. 1996. *Pediatr. Res.* **40**: 867–871.