

### Acute renal failure secondary to malignant hypertension induced thrombotic microangiopathy

*Kultigin Turkmen, MD, Yalcin Solak, MD,  
Hasan Esen, MD, Halil Z. Tonbul, MD.*

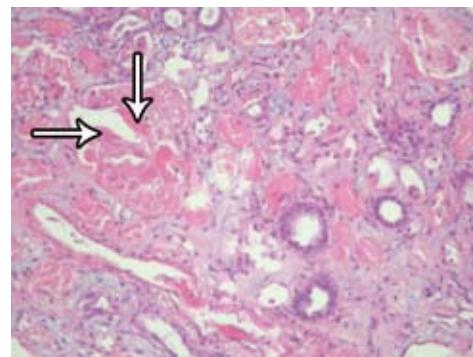
The thrombotic microangiopathy (TMA) represents a discreet group of disorders with common pathological features including fibrinoid necrosis, endothelial cell injury, and obstruction of vessels.<sup>1</sup> The clinical presentation of TMA includes microangiopathic hemolytic anemia, thrombocytopenia, and functional impairment of various organ systems. Hemolytic uremic syndrome (HUS) and thrombotic thrombocytopenic purpura (TTP) are among the common causes of TMA.<sup>2</sup> Patients with malignant hypertension are prone to TMA. Although the frequency of intrarenal TMA with malignant hypertension has not been well described, a study reported that 13% of patients with systemic TMA showed malignant hypertension.<sup>3</sup> The differential diagnosis of TMA may be difficult without knowledge of patient's history. Thereby we represent a patient with acute renal failure secondary to malignant hypertension induced TMA to imply the importance of hypertension as a cause of TMA.

A 76-year-old male was admitted to the emergency room with complaints of malaise, fatigue, headache, and decreased urinary output for a week. He had hypertension for 2 years, but he did not use any antihypertensive agent. On admission, his blood pressure was 200/130 mm Hg (equal in both arms) with a heart rate of 78 beats per minute and a temperature of 36°C. He had bilateral massive pitting edema. Heart auscultation was unremarkable. Bilateral crepitant rales at the bases of lungs were present on auscultation. Bilateral upper and lower extremity arteries were symmetrically palpated. No abdominal bruit was audible over the trajectory of renal arteries and abdominal aorta. Focal neurological deficit and blurred vision were not determined. Abdominal ultrasound (USG) showed normal kidney size, and ecogenity bilaterally. Prostate size and volume were 41x33x34 mm and 24 ml. Chest CT revealed bilateral pulmonary edema, and pleural effusion. Noteworthy initial biochemical results and whole blood count were as follows; blood urea nitrogen (BUN): 55 mg/dl (Normal range [NR]; 7-18 mg/dL), creatinine: 6.83 mg/dl (NR; 0.6-1.2 mg/dL), lactate dehydrogenase (LDH): 1800 U/L (NR; 50-150 U/L), platelet: 66.000/mm<sup>3</sup>. Urinalysis revealed trace protein, no red blood cells per high-power field. There was no active urinary sediment. Twenty-four-hour-urine protein was 1 gr. Anti-nuclear antibody; anti-extractable nuclear antigen, and anti-nuclear cytoplasmic antibody were negative. Serum

complement levels (C3 and C4) were normal. Hepatitis B surface antigen, anti-hepatitis B surface, anti-hepatitis A virus, and anti-hepatitis C virus antibodies were also negative.

We initiated hemodialysis therapy 3 times per week, and antihypertensive drugs including amlodipine 10 mg/day, bisoprolol 10 mg/day, doxazosin 4 mg/day, and perlinganite 3 mcg/min. On blood smear, schistocytes were 3% of observed red blood cells. Renal biopsy showed acute tubular necrosis and bright red thrombi (arrow) in glomerular capillary loop, which were consistent with TMA (Figure 1). After appropriate treatment of hypertension, platelet counts and serum LDH levels returned to normal values, and he did not require plasmapheresis.

Kidneys are commonly affected in thrombotic microangiopathies, which include disseminated intravascular coagulation, eclampsia/preeclampsia, HUS, TTP, and malignant hypertension.<sup>1</sup> In some cases, the presentation of the latter 2 entities may overlap. Patients with malignant hypertension often have a blood pressure above 200/140 mm Hg; however, the condition is defined as the presence of pupil edema, retinal hemorrhages, and exudates rather than absolute blood pressure levels.<sup>2</sup> In our case, the patient had malignant hypertension and acute renal failure secondary to TMA. Consistent findings supporting the diagnosis were the presence of fragmented red blood cells on the peripheral blood smear, elevated LDH level, presence of microvascular thrombi and mesangiocapillary proliferation in renal biopsy, and thrombocytopenia. These findings may be similar in both TTP, and malignant hypertension. However, the pathogenesis and treatment of these 2 entities are quite different. Differentiation of malignant hypertension from TTP is sometimes difficult because of sharing the same clinical and histological findings.<sup>2</sup> The levels of metalloproteinase named ADAMTS13 and its inhibitors may be helpful in differential diagnosis.<sup>4</sup> The



**Figure 1** - Renal biopsy showed acute tubular necrosis and bright red thrombi (arrow) in glomerular capillary loop.

treatment of TMA due to TTP is unique including plasmapheresis, the differentiation of these 2 diseases is essential.

Received 23rd January 2010. Accepted 21st June 2010.

From the Departments of Nephrology (Turkmen, Solak, Tönbül), and Pathology (Esen), Meram School of Medicine, Selçuk University, Konya, Turkey. Address correspondence and reprints request to: Dr. Kultigin Turkmen, Department of Nephrology, Meram School of Medicine, Selçuk University, Konya 42090, Turkey. Tel. +90 (538) 4927877. Fax. +90 (332) 2237121. E-mail: mdkt2010@yahoo.com

## References

1. Liapis H. Thrombotic microangiopathy involving the kidney: A histopathologic perspective. *Hippokratia* 2003; 7: 152-158.
2. Egan JA, Bandarenko N, Hay SN, Paradowski L, Goldberg R, Nickenleit V, et al. Differentiating thrombotic microangiopathies induced by severe hypertension from anemia and thrombocytopenia seen in thrombotic thrombocytopenia purpura. *J Clin Apher* 2004; 19: 125-129.
3. Espinosa G, Bucciarelli S, Cervera R, Lozano M, Reverter JC, de la Red G, et al. Thrombotic microangiopathic haemolytic anaemia and antiphospholipid antibodies. *Ann Rheum Dis* 2004; 63: 730-636.
4. Boctor FN, Prichard JW. Kidney involvement in thrombotic thrombocytopenic purpura and malignant hypertension. *Transfusion* 2009; 49: 1783-1784.

## Authorship entitlement

Excerpts from the Uniform Requirements for Manuscripts Submitted to Biomedical Journals updated November 2003.  
Available from [www.icmje.org](http://www.icmje.org)

The international Committee of Medical Journal Editors has recommended the following criteria for authorship; these criteria are still appropriate for those journals that distinguish authors from other contributors.

Authorship credit should be based on 1) substantial contributions to conception and design, or acquisition of data, or analysis and interpretation of data; 2) intellectual content; and 3) final approval of the version to be published. Authors should meet conditions 1, 2, and 3.

Acquisition of funding, collection of data, or general supervision of the research group, alone, does not justify authorship.

An author should be prepared to explain the order in which authors are listed.