

Maxillary expansion in the mixed dentition: rapid or semi-rapid?

Sabri İlhan Ramoğlu* and Zafer Sari**

Departments of Orthodontics, Faculties of Dentistry, *Erciyes University, Kayseri and **Selçuk University, Konya, Turkey

SUMMARY The purpose of this study was to investigate the effects of rapid maxillary expansion (RME) and semi-rapid maxillary expansion (SRME) in the mixed dentition period. The SRME group consisted of 18 patients (11 girls and 7 boys) with a mean age of 8.63 ± 1.09 years and the RME group 17 patients (11 girls and 6 boys) with a mean age of 8.78 ± 1.21 years. A splint type tooth- and tissue-borne modified bonded RME appliance was used, with the patients activating the screw two-quarter turns per day for the first week, followed by one-quarter turn every other day in the SRME group and two-quarter turns per day throughout treatment in the RME group. The average treatment time was 57.16 ± 21.52 and 21.23 ± 8.36 days for the SRME and RME groups, respectively. A Wilcoxon signed rank test was used to evaluate the treatment effects [pre-(T_0) – post-(T_1) treatment changes] for both the SRME and RME groups and a Mann-Whitney *U*-test to determine the differences between the two groups (T_0 - T_1 changes SRME versus T_0 - T_1 changes RME).

For both groups, the maxillary base, nasal cavity width and upper intercanine and intermolar distances were increased, and the upper molars tipped buccally. The only statistically significant ($P < 0.05$) difference between two groups was in inferior movement of posterior nasal spine (PNS) relative to the SN plane ($SN \perp PNS$). This measurement increased in both groups yet significantly more in the RME group. The results suggest that RME and SRME have similar effects on dentofacial structures both in the transverse, vertical, and sagittal planes.

Introduction

A crossbite is one of the most common transverse malocclusions in the posterior region of the dental arch (Ferrario *et al.*, 2003). The incidence of a posterior crossbite has been reported to be between 2.7 and 18.2 per cent in different populations (Kutin and Hawes, 1969; Thilander *et al.*, 1984; Da Silva Filho *et al.*, 1991; Sandikçioğlu and Hazar, 1997; Başçiftçi *et al.*, 2002; Tausche *et al.*, 2004). This entity may occur in the primary dentition and manifest itself as a constriction of the lateral dimension of the upper arch (Da Silva Filho *et al.*, 1991).

Different methods have been used to expand constricted maxillary arches. When evaluated on the basis of frequency of the activations, magnitude of the applied force, duration of the treatment, and patient age, different mechanics produce rapid, semi-rapid, or slow expansion (Sandikçioğlu and Hazar, 1997; Usumez and Uzel, 2008).

In rapid maxillary expansion (RME) protocols, a twice-daily activation schedule, which is most commonly proposed in the literature, was shown to produce residual loads during early treatment (Zimring and Isaacson, 1965). İşeri *et al.* (1998) reported that RME not only produced an expansion force at the intermaxillary suture but also caused high forces on various structures in the craniofacial complex. The retention of RME depends not only on bone formation in the intermaxillary suture but also on the creation of a stable relationship at the articulations of the maxilla and other bones of the facial skeleton (Isaacson and

Ingram, 1964; Zimring and Isaacson, 1965). Therefore, relatively slower expansion is recommended to produce less tissue resistance in the nasomaxillary structures (İşeri *et al.*, 1998).

Both Geran *et al.* (2006) and Sari *et al.* (2003) used a regimen of one activation per day in young patients and reported success with this protocol. However, Sari *et al.* (2003) stated that this regimen is not superior to the classic regimen of two-quarter turns per day and suggested evaluation of slower rhythms for RME in the mixed dentition. İşeri *et al.* (1998) suggested a slow expansion protocol immediately after the separation of the intermaxillary suture by RME in order to produce less tissue resistance. İşeri and Özsoy (2004) used semi-rapid maxillary expansion (SRME) which is different to the SRME protocol described by Mew (1977, 1983, 1997). Mew (1983) and Sandikçioğlu and Hazar (1997) used an activation rhythm of 1 mm per week whereas İşeri and Özsoy (2004) used a schedule of 2×0.2 mm per day for the first 5–6 days and 3×0.2 mm per week for the rest of the expansion in older adolescents and adults.

While the effects of RME on adolescents and young adults are well documented, there is limited information on the outcome of SRME in mixed dentition subjects. Therefore, the purpose of this study was to evaluate the short-term effects of SRME on the vertical, sagittal, and transverse planes in mixed dentition patients.

Subjects and methods

The sample comprised 35 Caucasian patients, 22 girls and 13 boys who applied to Department of Orthodontics of Selçuk University for orthodontic treatment. The inclusion criteria dictated no sagittal skeletal problem, either a functional unilateral or bilateral posterior crossbite with transverse deficiency, the first permanent molars erupted and no more than one missing maxillary tooth in the right and left sides of the dentition. All parents signed an informed consent form.

The subjects were randomly divided into two groups of SRME and RME. The SRME group consisted of 18 patients, 11 girls and 7 boys, with a mean age of 8.63 ± 1.09 years and the RME group 17 patients, 11 girls and 6 boys, with a mean age of 8.78 ± 1.21 years.

Appliance and activation

A splint type tooth- and tissue-borne modified bonded RME appliance (Basciftci and Karaman, 2002; Basciftci *et al.*, 2002; Orhan *et al.*, 2003; Sari *et al.*, 2003; Usumez *et al.*, 2003) was used for both groups (Figure 1). The activation of the screw was two-quarter turns per day for the first week followed by one-quarter turn per day every other day for the SRME group. The mean treatment time was 57.16 ± 21.52 days. In the RME group, the schedule

was two-quarter turns per day throughout treatment, and the mean treatment time was 21.23 ± 8.36 days.

Midpalatal suture opening was confirmed at the end of the first week on occlusal radiographs. Screw activation was ended when approximately 2 mm of overcorrection was achieved, and the screw was fixed by a ligature wire. The appliance was used as a fixed retainer for 14 days and then debonded. At the same appointment, a removable appliance was fabricated for retention.

Records and measurements

Lateral and frontal cephalometric radiographs and dental casts were taken before (T_0) and after (T_1) expansion. In order to determine the changes in molar inclination on frontal cephalometric radiographs, acrylic caps, which had partially embedded 0.7 mm thick and 10 mm long stainless steel wire positioned perpendicular to the occlusal surface, were individually constructed. The wire of the left cap was bent along on the edge to facilitate recognition of the left and right sides (Figure 2). The onlays were temporarily cemented with polycarboxylate luting cement on the first upper molars before exposure of the frontal cephalometric radiographs. The same caps were used for both the T_0 and T_1 records.

A total of 25 measurements, 18 on the lateral and three on frontal cephalometric radiographs, and four on dental casts, were assessed by one author (SIR). Lateral and frontal

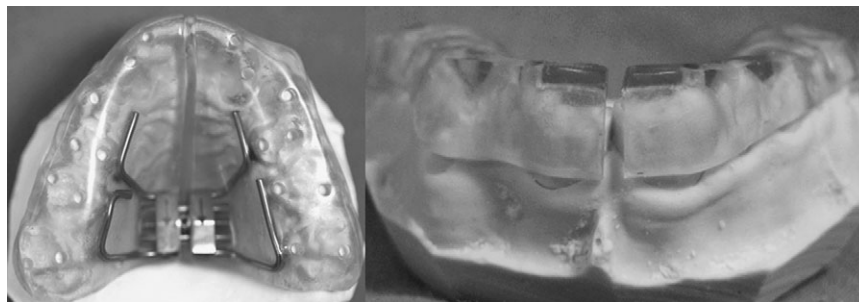


Figure 1 Modified acrylic bonded rapid maxillary expansion appliance.

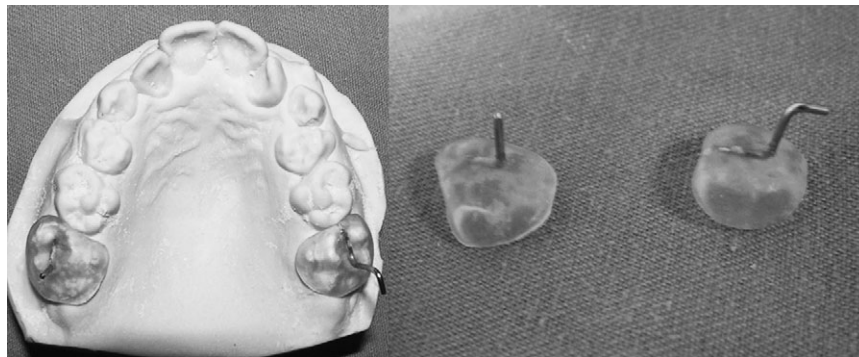


Figure 2 Acrylic caps constructed to determine buccolingual inclinations of the upper first molar.

cephalometric, and dental cast measurements are shown in Figures 3, 4 and 5, respectively.

Statistical analysis

Descriptive statistics, including the mean and standard deviation, were obtained for the data. To evaluate the T₀-T₁ changes for both the SRME and RME groups, a Wilcoxon signed-rank test and to determine the differences between the two groups (T₀-T₁ changes SRME versus T₀-T₁ changes RME), a Mann-Whitney U-test was used. The analyses were performed using the Statistical Package for Social Sciences (version 10.0.0, SPSS Inc., Chicago, Illinois, USA).

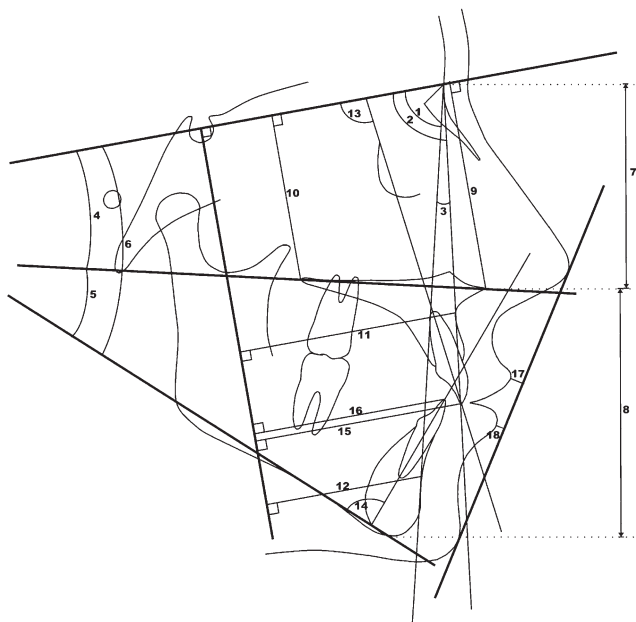


Figure 3 Lateral cephalograms—1: SNA (°), angle formed by the planes of sella-nasion and nasion-point A; 2: SNB (°), angle formed by the planes of sella-nasion and nasion-point B; 3: ANB (°), angle formed by the planes of nasion-point A and nasion-point B; 4: SNPP (°), angle formed by the sella-nasion plane and the palatal plane [anterior nasal spine (ANS)-posterior nasal spine (PNS)]; 5: MPPP (°), angle formed by the mandibular plane (gonion-menton) and the palatal plane; 6: SN[∧]MP (°), angle formed by the sella-nasion plane and the mandibular plane; 7: N_ ANS (mm), the distance between nasion and ANS; 8: ANS_Me (mm), the distance between ANS and menton; 9: SN[⊥]ANS (mm), the perpendicular distance of ANS to the sella-nasion plane; 10: SN[⊥]PNS (mm), the perpendicular distance of PNS to the sella-nasion plane; 11: SV[⊥]A (mm), the perpendicular distance of point A to the sella vertical plane (SV) was constructed through the sella, perpendicular to the sella-nasion plane; 12: SV[⊥]B (mm), the perpendicular distance of point B to the sella vertical plane constructed through the sella, perpendicular to the sella-nasion plane; 13: IsiPSN (°), angle formed between the sella-nasion plane and Isi plane, a plane from the superior central incisor's incisal edge through its root; 14: IiiPMP (°), angle formed between the mandibular plane and Iii plane, a plane from the inferior central incisor's incisal edge through its root; 15: SV[⊥]Isi (mm), the perpendicular distance of the incisal edge of superior central incisor to sella vertical plane; 16: SV[⊥]Iii (mm), the perpendicular distance of incisal edge of the inferior central incisor to sella vertical plane; 17: Ls_E (mm), the perpendicular distance of the most anterior point on the convexity of the superior lip to E plane that extends from the tip of the nose and the chin; 18: Li_E (mm), the perpendicular distance of the most anterior point on the convexity of the inferior lip to the E plane.

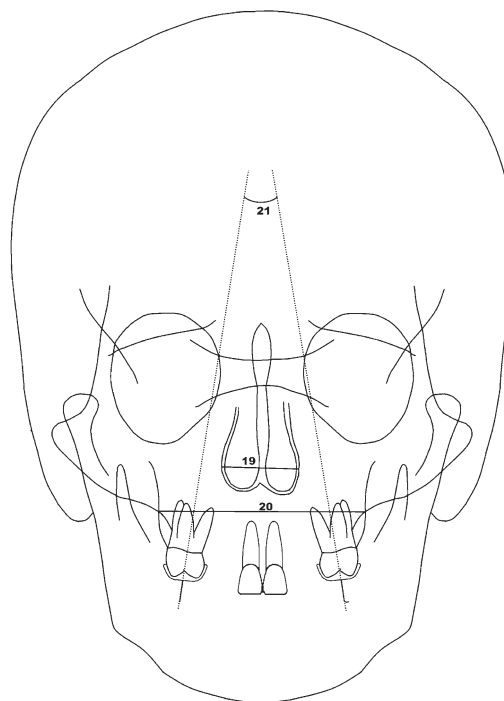


Figure 4 Frontal cephalograms—19: NC_CN (mm), nasal cavity width, the distance between left and right lateral piriform rims; 20: JL_JR (mm), maxillary skeletal width, the distance between left and right jugale points; 21: LARLAL (°), the angle formed between the long axes of the right and left first permanent molars.

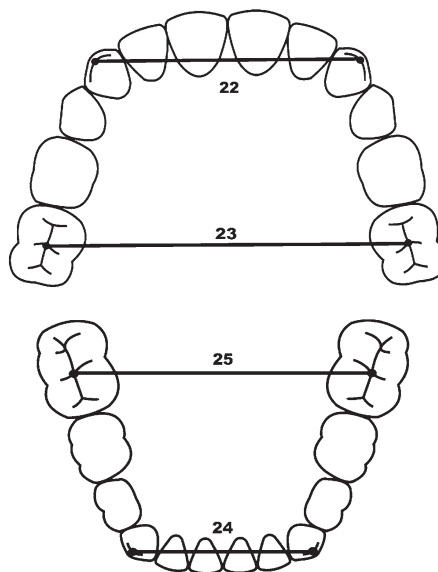


Figure 5 Dental casts—22: UC_UC (mm), the width between the upper canines; 23: UM_UM (mm), the width between the upper first molars; 24: LC_LC (mm), the width between the lower canines; 25: LM_LM (mm), the width between the lower first molars.

Method error

Approximately 1 month after the first measurements, 10 records from each group were randomly selected and

remeasured by the same author. Intra-examiner measurement error was calculated with Dahlberg's formula ($\sqrt{\Sigma d^2/2n}$). The smallest measurement error was 0.11 mm for lower molar width and the largest 1.38 degrees at the lower incisor plane and mandibular plane angle.

Results

Treatment changes in the SRME group

In the SRME group, statistically significant increases were found in SNA, IiiP[∧]MP, and MP[∧]PP angles, SN[⊥]PNS distance ($P < 0.05$), ANB angle, NC_CN, and LC_LC distances ($P < 0.01$), LAR[∧]LAL angle, JL_JR, upper canine (UC_UC), and upper molar (UM_UM) distances ($P < 0.001$; Table 1).

Treatment changes in the RME group

In the RME group, statistically significant increases were found in ANS_Me distance ($P < 0.05$), SN[∧]MP and MP[∧]PP angles, SN[⊥]PNS and LC_LC distances ($P < 0.01$), LAR[∧]LAL angle, NC_CN, JL_JR, UC_UC, and UM_UM distances

($P < 0.001$), whereas a decrease was noted in SV[⊥]B distance ($P < 0.05$; Table 2).

Comparison of the two groups

The only statistically significant difference between the two groups was in the amount of inferior movement of posterior nasal spine (PNS) point relative to the SN plane; SN[⊥]PNS distance showed a greater increase in the RME than in the SRME group ($P < 0.05$; Table 3).

Discussion

To determine any possible alterations in the position of the maxilla in the sagittal plane, SV[⊥]A and SNA measurements were considered. A statistically significant increase of 0.55 degrees was found in SNA at the end of treatment in the SRME group ($P < 0.05$). This finding was confirmed by the increase in ANB ($P < 0.01$). Whereas SNB and SV[⊥]B showed no significant difference, the increase in SNA was related to anterior movement of point A. On the other hand, SNA remained stable in the RME group. It has been observed in previous studies (Sandikçioğlu and

Table 1 Changes with treatment in the semi-rapid maxillary expansion group ($n = 18$).

Variables	Pre-treatment		Post-treatment		Test	
	Mean	SD	Mean	SD	P-value	Significance
<i>Lateral cephalogram</i>						
1 SNA (°)	76.97	2.45	77.52	2.32	0.039	*
2 SNB (°)	74.22	3.14	74.19	3.17	0.776	NS
3 ANB (°)	2.75	1.88	3.33	1.63	0.009	**
4 SN [∧] PP (°)	8.72	2.53	8.14	2.06	0.081	NS
5 MP [∧] PP (°)	30.75	5.42	31.44	5.95	0.045	*
6 SN [∧] MP (°)	39.47	5.51	39.61	6.19	0.537	NS
7 N_ANS (mm)	48.56	2.54	49.06	2.58	0.405	NS
8 ANS_Me (mm)	63.33	4.39	64.00	4.22	0.143	NS
9 SN [⊥] ANS (mm)	49.06	2.26	49.33	2.56	0.156	NS
10 SN [⊥] PNS (mm)	42.00	2.74	42.56	2.54	0.019	*
11 SV [⊥] A (mm)	55.86	4.12	55.69	4.15	0.605	NS
12 SV [⊥] B (mm)	42.36	6.93	42.19	6.85	0.470	NS
13 IsiP [∧] SN (°)	100.36	7.56	100.44	7.32	0.887	NS
14 IiiP [∧] MP (°)	90.08	7.43	91.42	6.78	0.017	*
15 SV [⊥] Isi (mm)	54.00	6.23	54.56	5.86	0.299	NS
16 SV [⊥] Iii (mm)	51.53	5.75	51.69	5.61	0.793	NS
17 Ls_E (mm)	2.33	2.61	2.22	2.09	0.954	NS
18 Li_E (mm)	0.58	2.66	0.33	2.70	0.412	NS
<i>Frontal cephalogram</i>						
19 NC_CN (mm)	28.86	3.07	30.56	2.37	0.001	**
20 JL_JR (mm)	62.89	2.60	64.81	2.68	0.000	***
21 LAR [∧] LAL (°)	16.03	10.13	26.61	12.28	0.000	***
<i>Dental casts</i>						
22 UC_UC (mm)	29.22	3.47	34.36	4.07	0.000	***
23 UM_UM (mm)	42.76	4.33	48.47	4.07	0.000	***
24 LC_LC (mm)	27.51	4.81	27.91	4.91	0.009	**
25 LM_LM (mm)	43.45	4.74	43.43	4.68	0.795	NS

* $P < 0.05$; ** $P < 0.01$; *** $P < 0.001$; NS, not significant.

Table 2 Changes with treatment in the rapid maxillary expansion group ($n = 17$).

Variables	Pre-treatment		Post-treatment		Test	
	Mean	SD	Mean	SD	P-value	Significance
<i>Lateral cephalogram</i>						
1 SNA (°)	77.64	3.30	78.02	4.04	0.342	NS
2 SNB (°)	75.24	3.64	75.00	3.81	0.359	NS
3 ANB (°)	2.41	2.52	3.03	3.00	0.089	NS
4 SN^PP (°)	9.50	3.09	9.41	3.76	0.535	NS
5 MP^PP (°)	30.59	4.60	32.26	4.92	0.001	**
6 SN^MP (°)	40.08	6.00	41.67	5.59	0.003	**
7 N_ANS (mm)	49.29	3.94	49.56	4.72	0.588	NS
8 ANS_Me (mm)	62.38	3.47	63.67	4.00	0.038	*
9 SN^ANS (mm)	49.85	3.31	50.50	3.98	0.096	NS
10 SN^PNS (mm)	41.82	2.87	42.97	3.26	0.001	**
11 SV^A (mm)	53.82	3.48	53.79	4.60	0.804	NS
12 SV^B (mm)	41.41	6.81	40.09	7.39	0.034	*
13 IsiP^SN (°)	99.88	8.97	99.65	8.91	0.924	NS
14 IiiP^MP (°)	88.68	5.41	88.56	5.60	0.668	NS
15 SV^Isi (mm)	52.32	4.94	52.24	5.66	0.525	NS
16 SV^Iii (mm)	50.53	4.61	49.97	5.27	0.111	NS
17 Ls_E (mm)	2.82	2.65	2.24	2.93	0.109	NS
18 Li_E (mm)	0.50	2.33	0.06	2.12	0.179	NS
<i>Frontal cephalogram</i>						
19 NC_CN (mm)	29.21	2.31	30.88	2.74	0.000	***
20 JL_JR (mm)	62.26	3.89	64.71	4.02	0.000	***
21 LAR^LAL (°)	10.47	8.65	19.82	7.98	0.000	****
<i>Dental casts</i>						
22 UC_UC (mm)	27.72	2.65	32.50	2.46	0.000	***
23 UM_UM (mm)	42.03	4.18	47.14	4.31	0.000	***
24 LC_LC (mm)	25.89	2.36	26.27	2.25	0.001	**
25 LM_LM (mm)	38.76	3.37	38.89	3.47	0.075	NS

* $P < 0.05$; ** $P < 0.001$; *** $P < 0.001$; NS, not significant.

Hazar, 1997; Akkaya *et al.*, 1999; Basciftci and Karaman, 2002; Sari *et al.*, 2003; Chung and Font, 2004) that SNA increases at the end of treatment. Chung and Font (2004) reported a statistically significant increase in SNA of 0.35 degrees but concluded that it may not be clinically significant. Da Silva Filho *et al.* (1991) also reported a similar increase in SNA of 0.50 degrees, which was insignificant in their study.

Another parameter used to determine anterior movement of the maxilla in the present study was SV^A, which did not show significant changes for either of the groups. This finding is similar to the results of Da Silva Filho *et al.* (1991) and Reed *et al.* (1999), whereas some authors (Sarver and Johnston 1989; Asanza *et al.*, 1997; Basciftci and Karaman, 2002; Sari *et al.*, 2003) reported movements of point A relative to the SV plane. In the present sample, point A moved forward in seven patients and backward in eight but did not move in three in the SRME group. In the RME group, it moved forward in five patients and backward in eight but did not move in four. Similar findings were also found for SNA. When the two groups were compared, no significant differences were observed for SV^A and SNA. Thus, RME and SRME have similar

effects on the maxilla in the sagittal plane. However, individually the maxilla might show different movement characteristics.

In the SRME group, MPPP and SN^PNS showed a statistically significant increase ($P < 0.05$). An increase in SN^PNS measurement means inferior movement of PNS. SN^ANS remained stable, which can be described as a counter clockwise rotation of the palatal plane and may be a reason for the increase in MP^PP angle. As ANS_Me, SV^B, and SNB were stable, it may be concluded that this alteration did not affect the vertical and sagittal position of the mandible; the changes occurred only at the level of PNS. The same measurement, SN^PNS, showed a statistically significant increase in the RME group ($P < 0.01$) as well as SN^MP, MP^PP ($P < 0.01$), and ANS_Me ($P < 0.05$). A statistically significant decrease was also determined for SV^B ($P < 0.05$). These alterations of SNMP, MPPP, ANS_Me, and SV^B indicate inferior and posterior movement of the mandible in the RME group. However, when the two groups were compared, the only statistically significant difference was found for SN^PNS ($P < 0.05$), which indicates more inferior movement of PNS in the RME group. This data were supported by the increase

Table 3 Comparison of change with treatment in the semi-rapid maxillary expansion (SRME) versus the rapid maxillary expansion (RME) group.

Variables	SRME group (n = 18)		RME group (n = 17)		Test	
	Mean	SD	Mean	SD	P-value	Significance
<i>Lateral cephalogram</i>						
1 SNA (°)	0.56	1.02	0.38	1.77	0.987	NS
2 SNB (°)	-0.02	1.32	-0.23	1.48	0.665	NS
3 ANB (°)	0.58	0.75	0.61	1.42	0.814	NS
4 SN [∧] PP (°)	-0.58	1.26	-0.08	1.93	0.739	NS
5 MP [∧] PP (°)	0.69	1.76	1.67	1.53	0.135	NS
6 SN [∧] MP (°)	0.14	2.08	1.59	1.72	0.057	NS
7 N ₁ ANS (mm)	0.50	1.91	0.26	2.15	0.691	NS
8 ANS ₁ Me (mm)	0.66	1.82	1.29	2.12	0.371	NS
9 SN [⊥] ANS (mm)	0.28	1.15	0.65	1.54	0.414	NS
10 SN [⊥] PNS (mm)	0.56	0.87	1.15	0.82	0.037	*
11 SV [⊥] A (mm)	-0.17	1.33	-0.03	1.61	0.947	NS
12 SV [⊥] B (mm)	-0.33	2.61	-1.32	2.33	0.313	NS
13 IsiP [∧] SN (°)	0.08	2.70	-0.24	2.79	0.842	NS
14 IiiP [∧] MP (°)	1.33	1.91	-0.12	2.40	0.842	NS
15 SV [⊥] Isi (mm)	0.55	2.16	-0.02	1.30	0.506	NS
16 SV [⊥] Iii (mm)	0.17	2.33	-0.56	1.42	0.506	NS
17 Ls ₁ E (mm)	-0.11	1.68	-0.58	1.34	0.265	NS
18 Li ₁ E (mm)	-0.25	1.25	-0.44	1.37	0.617	NS
<i>Frontal cephalogram</i>						
19 NC_CN (mm)	1.69	1.56	1.68	1.01	0.611	NS
20 JL_JR (mm)	1.92	1.11	2.38	1.44	0.378	NS
21 LAR [∧] LAL (°)	10.61	6.08	9.35	3.91	0.644	NS
<i>Dental casts</i>						
22 UC_UC (mm)	5.13	1.47	4.77	1.53	0.621	NS
23 UM_UM (mm)	5.71	1.66	5.11	1.81	0.322	NS
24 Lc ₁ LC (mm)	0.40	0.55	0.38	0.43	0.754	NS
25 LM_LM (mm)	-0.01	0.52	0.12	0.32	0.336	NS

* $P < 0.05$; ** $P < 0.01$; *** $P < 0.001$; NS, not significant.

in SN[∧]MP and ANS₁Me and the decrease in SV[⊥]B in the RME group. This alteration in lower face height has been reported by several authors (Byrum, 1971; Da Silva Filho *et al.*, 1991; Sandikçioğlu and Hazar, 1997; Sari *et al.*, 2003; Chung and Font, 2004). Despite the fact that the difference between the two groups in the amount of inferior movement of PNS was as low as 0.59 mm, which is probably clinically insignificant, it might be taken into consideration in vertically growing patients. Inferior movement of PNS may also play a role in the increase of posterior nasal space airway; however, the clinical significance of this requires further investigation.

The upper incisors showed a stable position relative to SV[⊥]Isi and IsiP[∧]SN for both groups. This finding is in agreement with previous studies (Asanza *et al.*, 1997; Basciftci and Karaman, 2002; Sari *et al.*, 2003; Chung and Font, 2004). In the RME group, the lower incisors were stable when considered with IiiP[∧]MP and SV[⊥]Iii measurements. For the SRME group, SV[⊥]Iii did not show a statistically significant difference, whereas IiiP[∧]MP increased 1.34 degrees ($P < 0.05$). When the method error values were considered, the largest error of 1.38 degrees was found for IiiP[∧]MP measurement. As the recorded

change for this parameter was very close to the method error value, this value was not taken into consideration. Furthermore, when the groups were compared, no statistically difference was noted for the position of the lower incisors.

The soft tissue variables, Ls₁E and Li₁E, were stable at T₁ in both groups. Similar findings were reported by Basciftci and Karaman (2002).

It was found that nasal cavity measurement increased significantly in both the RME ($P < 0.001$) and SRME ($P < 0.01$) groups. This finding is in agreement with previous investigations (Haas, 1965; Özgen *et al.*, 1994; Memikoglu and Iseri, 1999; Cross and McDonald, 2000; Akkaya *et al.*, 2002; Basciftci and Karaman, 2002; Basciftci *et al.*, 2002; Sari *et al.*, 2003; Chung and Font, 2004; Doruk *et al.*, 2004; İşeri and Özsoy, 2004). No difference was found between the two groups in the amount of this increase.

Increases in JL_JR distance, measured to evaluate the amount of expansion in the maxillary base, were statistically significant in both groups ($P < 0.001$). This increase was also found in several previous studies (Memikoglu and Iseri, 1999; Cross and McDonald, 2000; Basciftci and Karaman, 2002; Sari *et al.*, 2003; Chung and Font,

2004; İşeri and Özsoy, 2004). When the amounts of the increases were compared, the two groups showed similar expansion rates.

Another parameter in the transverse plane is LAR^ΔLAL. The changes in this parameter represent the amount of molar tipping in the buccolingual direction. This tipping is a result of a combination of alveolar and molar tipping (Haas, 1961; Bishara and Staley, 1987). In the present study, tipping occurred in both groups ($P < 0.001$) in agreement with previous studies (Hicks 1978; Asanza *et al.*, 1997; Basciftci and Karaman, 2002; Sari *et al.*, 2003; Davidovitch *et al.*, 2005; Garib *et al.*, 2005; Podesser *et al.*, 2007; Rungcharassaeng *et al.*, 2007). No difference was found between the RME and SRME groups.

According to the dental cast measurements, UM_UM and UC_UC width values increased in both groups as expected after maxillary expansion ($P < 0.001$). Increases in UM_UM (Haas, 1961; Küçükkeleş and Hamid Waheed, 1995; Sandikçioğlu and Hazar, 1997; Akkaya *et al.*, 1998; Memikoglu and Iseri, 1999; Reed *et al.*, 1999; Cross and McDonald, 2000; Basciftci and Karaman, 2002; Sari *et al.*, 2003; Chung and Font, 2004; İşeri and Özsoy, 2004; Garib *et al.*, 2005) and UC_UC (Sandikçioğlu and Hazar, 1997; Akkaya *et al.*, 1998; Memikoglu and Iseri, 1999; Basciftci and Karaman, 2002; Sari *et al.*, 2003) have been reported. However, no difference was found between the two groups in the present study in the amount of expansion.

Another parameter measured on the dental casts was lower molar (LM_LM) width; no significant changes were recorded in either of the groups. This is in accordance with the findings of Basciftci and Karaman (2002), but different from many other authors (Haas, 1961; Sandstrom *et al.*, 1988; Akkaya *et al.*, 1998; İşeri and Özsoy, 2004; Lima *et al.*, 2004). Haas (1980) stated that the more inferior position of the tongue and the increased clearance of buccinator muscles from the mandibular arch, as a result of the body of the appliance and the following maxillary expansion, lead to uprighting and buccal movement of the mandibular posterior teeth. However, the results of the current investigation conflict with this described mechanism. First, although the volume of the appliance used in the current study was larger than that of the Haas appliance, no expansion was observed in the lower arch. Second, despite the duration of the expansion period and the tongue being positioned inferiorly for a longer time period in the SRME group, no difference was observed between groups. While the disocclusion effect of the acrylic cap splint does not seem to be a valid reason for mandibular arch expansion, İşeri and Özsoy (2004) and Akkaya *et al.* (1998) reported an increase in LM_LM with a similar appliance. A possible explanation for the different results among studies may be differences in the age groups. The mean ages for the RME and SRME groups were 8.78 and 8.63 years, respectively, in the current study, 14.75 years in the study of İşeri and Özsoy (2004), and 11.96 and 12.31 years in the investigation

of Akkaya *et al.* (1998). McNamara (2000) and Wendling *et al.* (2005) emphasized that the lower posterior teeth might erupt more lingually due to constriction of the maxillary arch. When treatment is undertaken at later ages, lingual eruption, in other words compensation of the mandibular teeth, may increase and after expansion of the maxilla, the amount of decompensation and buccal movement of the lower posterior teeth may increase. In addition to the previously described mechanism by Haas (1980), the amount of compensation in the lower arch may be responsible for the expansion of the mandibular posterior teeth. In this study, no changes were observed in LM_LM measurement while LC_LC measurement increased significantly in both groups ($P < 0.001$). However, the LC_LC measurement may not be considered reliable due to mobility of the primary canines used in the measurement at this developmental stage.

In the RME protocol, as the activation is faster than the SRME, shorter active treatment periods and chair side time is an advantage. Another advantage may be the shorter bonded appliance wear which negatively affects the oral hygiene.

Conclusion

The results suggest that the RME and SRME have a similar effect on dentofacial structures in the transverse, vertical, and sagittal planes. Whether the amount of relapse would be less with SRME due to a decrease in residual stresses in dentofacial structures should be evaluated further.

Address for correspondence

Dr Sabri İlhan Ramoğlu
 Dişhekimliği Fakültesi
 Erciyes Üniversitesi
 Ortodonti A.D.
 Melikgazi
 Kampüs
 Kayseri 38039
 Turkey
 E-mail: ilhanramoglu@yahoo.com

Funding

Selcuk University Research Projects (2003–204).

References

- Akkaya S, Lorenzon S, Ucem T T 1998 Comparison of dental arch and arch perimeter changes between bonded rapid and slow maxillary expansion procedures. *European Journal of Orthodontics* 20: 255–261
- Akkaya S, Lorenzon S, Ucem T T 1999 A comparison of sagittal and vertical effects between bonded rapid and slow maxillary expansion procedures. *European Journal of Orthodontics* 21: 175–180

- Akkaya S, Gülsen A, Taner-Sarisory L, Balos B 2002 Evaluation of the effects of maxillary expansion on the nasopharyngeal area. *World Journal of Orthodontics* 3: 211–216
- Asanza S, Cisneros G J, Nieberg L G 1997 Comparison of Hyrax and bonded expansion appliances. *Angle Orthodontist* 67: 15–22
- Basciftci F A, Karaman A I 2002 Effects of a modified acrylic bonded rapid maxillary expansion appliance and vertical chin cap on dentofacial structures. *Angle Orthodontist* 72: 61–71
- Basciftci F A, Mutlu N, Karaman A I, Malkoc S, Küçükkolbası H 2002 Does the timing and method of rapid maxillary expansion have an effect on the changes in nasal dimension. *Angle Orthodontist* 72: 118–123
- Başçıftçi F A, Demir A, Uysal T, Sarı Z 2002 Prevalence of orthodontic malocclusions in Konya region school children. *Turkish Journal of Orthodontics* 15: 92–98
- Bishara S E, Staley R N 1987 Maxillary expansion: clinical implications. *American Journal of Orthodontics and Dentofacial Orthopedics* 91: 3–14
- Byrum Jr A G 1971 Evaluation of anterior-posterior and vertical skeletal change vs. dental change in rapid palatal expansion cases as studied by lateral cephalograms. *American Journal of Orthodontics* 60: 419 (abstract)
- Chung C H, Font B 2004 Skeletal and dental changes in the sagittal, vertical, and transverse dimensions after rapid palatal expansion. *American Journal of Orthodontics and Dentofacial Orthopedics* 126: 569–575
- Cross D L, McDonald J P 2000 Effect of rapid maxillary expansion on skeletal, dental, and nasal structures: a postero-anterior cephalometric study. *European Journal of Orthodontics* 22: 519–528
- Da Silva Filho O G, Boas M C, Capelozza Filho L 1991 Rapid maxillary expansion in the primary and mixed dentitions: a cephalometric evaluation. *American Journal of Orthodontics and Dentofacial Orthopedics* 100: 171–181
- Davidovitch M, Efstathiou S, Sarne O, Vardimon A D 2005 Skeletal and dental response to rapid maxillary expansion with 2- versus 4-band appliances. *American Journal of Orthodontics and Dentofacial Orthopedics* 127: 483–492
- Doruc K, Bicakci AA, Basciftci F A, Agar U, Babacan H 2004 A comparison of the effects of rapid maxillary expansion and fan-type maxillary expansion on dentofacial structures. *Angle Orthodontist* 74: 184–194
- Ferrario V F, Garattini G, Colombo A, Filippi V, Pozzoli S, Sforza C 2003 Quantitative effects of a nickel-titanium palatal expander on skeletal and dental structures in the primary and mixed dentition: a preliminary study. *European Journal of Orthodontics* 25: 401–410
- Garib D G, Henriques J F, Janson G, Freitas M R, Coelho R A 2005 Rapid maxillary expansion—tooth tissue-borne versus tooth-borne expanders: a computed tomography evaluation of dentoskeletal effects. *Angle Orthodontist* 75: 548–557
- Geran R G, McNamara J A, Baccetti T, Franchi L, Shapiro L M 2006 A prospective long-term study on the effects of rapid maxillary expansion in the early mixed dentition. *American Journal of Orthodontics and Dentofacial Orthopedics* 129: 631–640
- Haas A J 1961 Rapid expansion of the maxillary dental arch and nasal cavity by opening the mid-palatal suture. *Angle Orthodontist* 31: 73–90
- Haas A J 1965 The treatment of maxillary deficiency by opening the midpalatal suture. *Angle Orthodontist* 35: 200–217
- Haas A J 1980 Long-term posttreatment evaluation of rapid palatal expansion. *Angle Orthodontist* 50: 189–217
- Hicks E P 1978 Slow maxillary expansion: a clinical study of the skeletal vs dental response in low magnitude force. *American Journal of Orthodontics* 73: 121–141
- Isaacson R J, Ingram A H 1964 Forces produced by rapid maxillary expansion. II. Forces present during treatment. *Angle Orthodontist* 34: 261–270
- İşeri H, Özsoy S 2004 Semirapid maxillary expansion—a study of long-term transverse effects in older adolescents and adults. *Angle Orthodontist* 74: 71–78
- İşeri H, Tekkaya A E, Öztan Ö, Bilgiç S 1998 Biomechanical effects of rapid maxillary expansion on the craniofacial skeleton, studied by the finite element method. *European Journal of Orthodontics* 20: 347–356
- Küçükkeleş N, Hamid Waheed U H 1995 Dental expansion and arch perimeter changes following rapid maxillary expansion with splint type of device. *Turkish Journal of Orthodontics* 8: 209–213
- Kutin G, Hawes R R 1969 Posterior crossbites in the deciduous and mixed dentition. *American Journal of Orthodontics* 56: 491–504
- Lima A C, Lima A L, Lima Filho R M A, Oyen O J 2004 Spontaneous mandibular arch response after rapid palatal expansion: a long-term study on Class I malocclusion. *American Journal of Orthodontics and Dentofacial Orthopedics* 126: 576–582
- McNamara J A 2000 Maxillary transverse deficiency. *American Journal of Orthodontics and Dentofacial Orthopedics* 117: 567–570
- Memikoglu T U, İseri H 1999 Effects of a bonded rapid maxillary expansion appliance during orthodontic treatment. *Angle Orthodontist* 69: 251–256
- Mew J R 1977 Semi-rapid maxillary expansion. *British Dental Journal* 143: 301–306
- Mew J 1983 Relapse following maxillary expansion. A study of twenty-five consecutive cases. *American Journal of Orthodontics* 83: 56–61
- Mew J 1997 Rapid maxillary expansion. *Angle Orthodontist* 67: 404 (letter)
- Orhan M, Üsümez S, Malkoc S 2003 Modified bonded rapid maxillary expansion appliance. *World Journal of Orthodontics* 4: 119–125
- Özgen M, Aksoy AÜ, Tezcan Ş, Tosun Y 1994 Frontal cephalometric evaluation of transversal effects of rapid maxillary expansion. *Turkish Journal of Orthodontics* 7: 26–27
- Podesser B, Williams S, Crismani A G, Bantleon H P 2007 Evaluation of the effects of rapid maxillary expansion in growing children using computer tomography scanning: a pilot study. *European Journal of Orthodontics* 29: 37–44
- Reed N, Ghosh J, Nanda R S 1999 Comparison of treatment outcomes with banded and bonded RPE appliances. *American Journal of Orthodontics and Dentofacial Orthopedics* 116: 31–40
- Runghcharassaeng K, Caruso J M, Kan J Y, Kim J, Taylor G 2007 Factors affecting buccal bone changes of maxillary posterior teeth after rapid maxillary expansion. *American Journal of Orthodontics and Dentofacial Orthopedics* 132: 428.e1–e8
- Sandıkçioğlu M, Hazar S 1997 Skeletal and dental changes after maxillary expansion in the mixed dentition. *American Journal of Orthodontics and Dentofacial Orthopedics* 111: 321–327
- Sandstrom R A, Klapper L, Papaconstantinou S 1988 Expansion of the lower arch concurrent with rapid maxillary expansion. *American Journal of Orthodontics and Dentofacial Orthopedics* 94: 296–302
- Sari Z, Uysal T, Usumez S, Basciftci F 2003 Rapid maxillary expansion. Is it better in the mixed or in the permanent dentition? *Angle Orthodontist* 73: 654–661
- Sarver D M, Johnston M W 1989 Skeletal changes in vertical and anterior displacement of the maxilla with bonded rapid palatal expansion appliances. *American Journal of Orthodontics and Dentofacial Orthopedics* 95: 462–466
- Tausche E, Luck O, Harzer W 2004 Prevalence of malocclusions in the early mixed dentition and orthodontic treatment need. *European Journal of Orthodontics* 26: 237–244
- Thilander B, Wahlund S, Lennartsson B 1984 The effect of early interceptive treatment in children with posterior cross-bite. *European Journal of Orthodontics* 6: 25–34
- Usumez M, Uzel I 2008 Evaluation of rapid maxillary expansion and quad-helix in the late mixed dentition period. *Turkish Journal of Orthodontics* 21: 187–195
- Usumez S, İşeri H, Orhan M, Basciftci F A 2003 Effect of rapid maxillary expansion on nocturnal enuresis. *Angle Orthodontist* 73: 532–538
- Wendling L K, McNamara J A, Franchi L, Baccetti T 2005 A prospective study of the short-term treatment effects of the acrylic-splint rapid maxillary expander combined with the lower Schwarz appliance. *Angle Orthodontist* 75: 7–14
- Zimring J F, Isaacson R J 1965 Forces produced by rapid maxillary expansion. III. Forces present during retention. *Angle Orthodontist* 35: 178–186